

## Cryptosporidiosis-Associated Lymphocytic Colitis

Leonard B. Weinstock, MD<sup>1</sup>,  
Zahid Kaleem, MD<sup>2</sup> and  
Michael B. Gutwein, MD<sup>3</sup>

doi:10.1038/ajg.2013.172

**To the Editor:** Lymphocytic colitis (LC) is a microscopic condition responsible for watery diarrhea, which can be difficult to treat and for which an underlying etiology can be difficult to find (1). In the histological disorders of microscopic colitis, there appears to be an overlap of LC and collagenous colitis (CC): abnormal numbers of intraepithelial lymphocytes are found in 45% (40–50%) with CC and an abnormal subepithelial collagen band are found in 16% of LC (13–20%) (2). In a 9-month period, four gastroenterologists diagnosed 14 patients with LC in an outpatient endoscopy center in St Louis, Missouri. In contrast, 20 cases of CC were diagnosed during the same time period. Two of the LC patients were subsequently diagnosed with an underlying infection with cryptosporidiosis and both had pathological abnormalities in the duodenum. Each patient had negative tTG and deaminated gliadin antibodies along with normal total immunoglobulin-A levels.

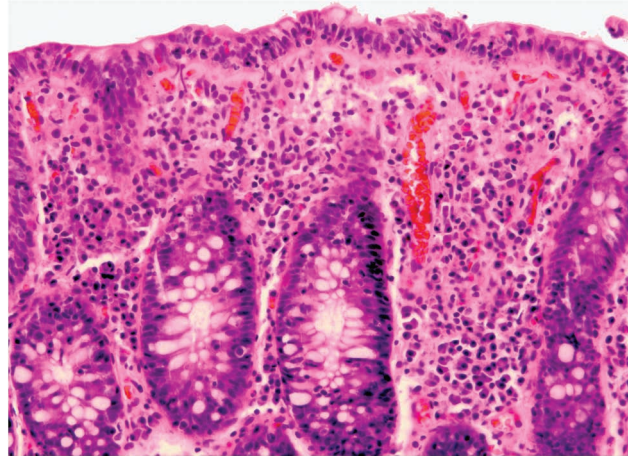
A 57-year-old completely healthy man presented with a 6-month history of progressively worsening painless watery diarrhea. His home had intermittent sewer back-ups and he was in the habit of drinking large quantities of tap water. The day before having a grossly normal colonoscopy with ileoscopy, he had 50 painless watery stools in 24 h. He was admitted for intravenous fluids after the colonoscopy. Upper endoscopy was performed the following day.

Colon biopsies were positive for LC (Figure 1). Duodenal biopsies showed infiltration by intraepithelial lymphocyte[s] with blunting of some of the villi. A stool specimen

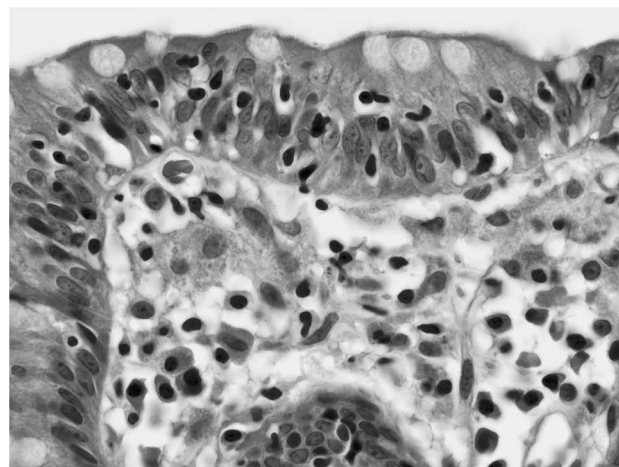
tested positive for the cryptosporidium antigen on hospital day 2. Review of both biopsy specimens failed to reveal infectious organisms. His HIV test was negative. Treatment with nitazoxanide 750 mg three times a day for 7 days led to complete remission, which was verified by office follow-up 1 month later.

An 80-year-old man presented with a 5-month history of progressively worsening painless watery diarrhea and general-

ized weakness. The diarrhea started 14 days after a vacation in Turkey, at which time he was taking 5 mg of prednisone for polymyalgia rheumatic for the previous 4 weeks. He had 5–8 stools per day with episodes of fecal incontinence. Stool cultures and standard examination for ova and parasites were negative. Colonoscopy with ileoscopy was grossly normal. Biopsies were positive for LC (Figure 2). His diarrhea responded well to two 6-week courses of budesonide



**Figure 1.** Colon biopsy shows intraepithelial lymphocytosis involving surface epithelium and crypts. The surface epithelium shows a greater degree of lymphocytosis with 48 intraepithelial lymphocytes/100 epithelial cells. The lamina propria shows an increased number of plasma cells. Thickening of subepithelial basement membrane, acute inflammatory cells, and eosinophils are absent. (Hematoxylin–eosin (H&E) stain, original magnification  $\times 400$ ).



**Figure 2.** The colon biopsy shows intraepithelial lymphocytosis involving surface epithelium and crypts with 45 intraepithelial lymphocytes/100 epithelial cells. The surface epithelium shows lymphocytosis with damage to the epithelial cells. The lamina propria shows an increased number of plasma cells and a few histiocytes. (Hematoxylin–Eosin (H&E) stain, original magnification  $\times 1,000$ ).

with the last followed by tapering program over 2 months. Diarrhea rapidly returned with cessation of the steroid. Treatment with bismuth also helped the diarrhea, but neither treatment helped his fatigue. He traveled to his winter home and his gastroenterologist in Florida performed upper endoscopy, which revealed scattered areas of villous atrophy and intraepithelial lymphocytes. A stool specimen for cryptosporidium antigen was positive. Treatment with nitazoxanide 750 mg three times a day for 3 days led to complete remission of diarrhea and gradual improvement in his fatigue, which was verified by follow-up 1 month later.

Cryptosporidiosis-associated LC has previously been reported in AIDS patients (3). In our two patients who had minimal to no evidence of immune suppression, successful response to antibiotic treatment and associated duodenal pathology strengthens the association of chronic cryptosporidiosis infection and LC. The colonic pathological change could be a direct response by lymphocytes or possibly an autoimmune epiphenomenon. Protozoa attach themselves to the epithelial surface and produce severe profuse, watery diarrhea and are best known to affect the immunocompromised

host (2). Duodenal biopsies may include increased intraepithelial lymphocytes and villous flattening; visualization of the single-cell protozoan is difficult to identify (2). Microscopic colitis, including LC causing diarrhea or irritable bowel syndrome, has been reported in studies from India, Bangladesh, and Turkey, but no data on stool testing was provided (3–5). The etiology for LC is most often blamed on medications (ticlopidine, carbamazepine, ranitidine, and nonsteroidal anti-inflammatory drugs) but other luminal agents, autoimmune diseases including celiac disease, eosinophils, genetics (human leukocyte antigen), biliary acid-associated diarrhea, alterations of pericryptal fibroblasts, infections, and small intestinal bacterial overgrowth are other considerations (1,2,8). In light of the present observations, cryptosporidiosis should be included in the differential diagnosis of LC in both immune compromised and normal hosts.

#### CONFLICT OF INTEREST

The authors declare no conflict of interest.

#### REFERENCES

1. Ianiro G, Cammarota G, Valerio L *et al*. Microscopic colitis. *World J Gastroenterol* 2012;18:6206–15.
2. Rasmussen MA, Munch LK. Systematic review: are lymphocytic colitis and collagenous colitis two subtypes of the same disease—microscopic colitis? *Aliment Pharmacol Ther* 2012;36:79–90.
3. Pita-Fernández L, Vargas-Castrillón J, Pazos C *et al*. Colitis by *Cryptosporidium* as initial manifestation of acquired immunodeficiency syndrome. *Rev Esp Enferm Dig* 2006;98:621–3.
4. Rotterdam H. Tissue diagnosis of selected AIDS-related opportunistic infections. *Am J Surg Pathol* 1987;11S1:3–15.
5. Falodia S, Makharia GK, Sateesh J *et al*. Spectrum of microscopic colitis in a tertiary care centre in India. *Trop Gastroenterol* 2007;28:121–5.
6. Rahman MA, Raihan AS, Ahamed DS *et al*. Symptomatic overlap in patients with diarrhea predominant irritable bowel syndrome and microscopic colitis in a sub group of Bangladeshi population. *Bangladesh Med Res Counc Bull* 2012;38:33–8.
7. Erdem L, Yildirim S, Akbayir N *et al*. Prevalence of microscopic colitis in patients with diarrhea of unknown etiology in Turkey. *World J Gastroenterol* 2008;14:4319–23.
8. Stoicescu A, Andrei M, Becheanu G *et al*. Microscopic colitis and small intestinal bacterial overgrowth—diagnosis behind the irritable bowel syndrome? *Rev Med Chir Soc Med Nat Iasi* 2012;116:766–72.

---

<sup>1</sup>Washington University School of Medicine, St Louis, Missouri, USA; <sup>2</sup>Missouri Baptist Medical Center, St Louis, Missouri, USA; <sup>3</sup>St Louis Infectious Disease, St Louis, Missouri, USA. Correspondence: Leonard B. Weinstock, MD, Washington University School of Medicine, 11525 Olde Cabin Road, St Louis, Missouri 63141, USA. E-mail: lw@giddoctor.net